

The Distally Based Saphenous Fasciocutaneous Flap Based on Fascial Pedicled Saphenous Neuro-Vascular Bundle for Reconstruction of Soft Tissue Defects Around the Knee and Superior Third of the Tibia

MOHAMED IBRAHIM HASSAN ZEIDAN, M.D.

The Department of Plastic and Reconstructive Surgery, Faculty of Medicine, Al-Azhar University, Cairo

ABSTRACT

The distally based saphenous flap is a fascio-cutaneous flap of the lower leg based on the saphenous artery, great saphenous vein, and saphenous nerve. We have been used it successfully (based on 5cm. Width fascial pedicle) in 12 patients for reconstruction of soft tissue defects around the knee and superior third of the tibia between April of 2010 and August of 2012. Data was obtained from all patients regarding age, sex, mechanism of injuries, location and size of defects, comorbidities, operative technique used, operative time, complications, and time of follow-up. The sizes of these flaps ranged from 5x12cm to 5x18cm. Donor sites were closed primarily. The advantages of this flap are: It has a long vascular pedicle, it has a good diameter, easier vascular dissection in tissue planes, thin flap (not exceeding 1cm. In thickness), and excellent dual venous drainage. One interesting feature of the flap is its lymphatic anatomy; two major lymphatic trunks run along the length of the flap immediately next to the long saphenous vein. Thus the flap has the potential to be used as a lymphatic bridge, with direct lymphatic anastomoses proximally and distally. All flaps had good perfusion and 9 flaps (75%) survived completely with Partial necrosis of the tip of the flap was encountered in three cases (25%). Minor donor site morbidity occurred in 3 cases (25%). The aim of this study was to analyse the easiness, versatility, and outcome of this flap.

INTRODUCTION

Soft tissue defects over the knee and superior third of the tibia, complicated by exposure of bone, tendon, metal fixation devices or prostheses, require aggressive management. Many local flaps have been devised and used successfully for reconstruction of these soft tissue defects but there can be donor site problems postoperatively [1-4]. This donor site morbidity can be minimised if the donor site is closed primarily with the partially [4] or totally [5] preserved skin. Also, larger studies in multimorbid patients have shown partial flap necrosis, epidermolysis, and wound dehiscence to be the most common complications [6,7].

The distally based Saphenous fasciocutaneous flap used successfully to cover soft tissue defects around the knee and superior third of the tibia. The skin territory supplied by this artery is large and includes the anteromedial third of the leg [8,9] The size of these flaps ranged from 5x12cm to 5x18cm. The diameter of the saphenous artery ranges from 1.7 to 2.2mm. The saphenous artery flap was first used as a free flap [8]. A gastrocnemius, soleus, and distally-based vastus lateralis muscle or musculocutaneous flap can be added, and large, complex spaces can be closed with adequate overlap of structures and without excessive tension to form a watertight closure of the joint [10-12]. An island fasciocutaneous flap also used to cover an injured around the knee [4]. Adipofascial flaps of the lower leg, which has less donor site morbidity than fasciocutaneous flaps used to cover a defect over the knee [5,13].

In the present series, the distally based saphenous fasciocutaneous flap (based on a fascial pedicle) has been shown to be a useful alternative for reconstruction of soft tissue defects around the knee and superior third of the tibia and gave satisfactory results with minimal postoperative morbidity for either donor or recipient sites.

PATIENTS AND METHODS

We retrospectively reviewed 20 patients treated with saphenous fasciocutaneous flap to reconstruct soft tissue defects over the knee and superior third of the tibia between April of 2010 and August of 2012. The hospital database was used to identify all patients. Data was obtained regarding age, sex, comorbidities, mechanism of injuries, location and

size of defects, operative technique used, operative time, complications, and time of follow-up.

Anatomy:

The saphenous artery which supply the flap is one of the two branches of the descending genicular artery originating from the superficial femoral artery immediately before the femoral artery pass through the hiatus in adductor magnus about 10-15cm above the knee [8]. The descending genicular artery and saphenous nerve pierce the fascia over the femoral artery within 2cm of its origin and run distally under cover of Sartorius for a distance of 12 to 15cm. The artery divides into musculo-articular, periosteal, and saphenous branches. The diameter of the saphenous artery ranges from 1.7 to 2.2mm. It is accompanied by two vena comitantes and the saphenous nerve and descends under Sartorius for about a hand's breadth. Here it gives off branches to supply the Sartorius and several fascio-cutaneous perforators which pass round the edge of the muscle to reach the skin [8] (Fig. 1). We could use standard points for direct exposure of the artery. Point "A" is at a distance of 2.5-3cm. Medial to the tip of femoral condyle. Point "B" is at a distance of 4-5cm. Behind the tibial tuberosity. Point "C" at 2-3cm. Of distal extension of the line connecting point A and point B.

After leaving the adductor canal, the saphenous artery runs distally behind the Sartorius muscle and enters the subcutaneous tissues below the medial condyle of the tibia. Beyond this point, this artery is referred to as the distal saphenous artery [8,9] and continues on distally to reach the upper medial aspect of the lower leg [1]. Along its descending course, the saphenous artery supplies a large area of skin 10cm above the knee on the medial thigh via its cutaneous branches and 20cm below the knee on the anteromedial aspect of the leg via the distal saphenous artery [8]. The skin of the medial aspect of the leg is also supplied by the septocutaneous vessels of the posterior tibial artery [14]. The proximal group of perforators of this artery are located about 8cm below the knee joint [15]. There are good anastomoses between the saphenous artery and the proximal perforators of the posterior tibial artery in the proximal part of the medial aspect of the lower leg. These anastomoses provide an additional blood supply for large saphenous artery flaps [15] (Fig. 1).

Surgical technique:

Preoperatively, with the patient standing, the sartorius muscle is indicated by a line drawn from the anterior superior iliac spine to the medial

condyle distal and posterior to the tibial tubercle. The course of the great saphenous vein is similarly marked from the fossa ovalis to the knee (just posterior to the insertion of the sartorius muscle). The apex to the subsartorial canal 9cm distal to the inguinal ligament is marked. Similarly, the entrance to the adductor hiatus is indicated 8-9cm proximal to the adductor tubercle. These two points represent both the proximal and distal extents of the subsartorial canal [17]. Under general or epidural anaesthesia, a tourniquet was used in all cases. The proposed flap is marked on the medial aspect of the proximal part of the lower leg; the anterior edge of the flap is along the medial border of the tibia. In order to establish the vascular topography, the elevation must proceed from proximal to distal and commence with an incision over Sartorius with its distal end some 12cm. The proximal base, including the saphenous vessels in the middle of the flap, can be designed as wide as 5cm. Flap dissections is aided by the use of surgical loupes (x 2.5). The skin incision is deepened through the epidermis and dermis to the subcutaneous tissue where the superficial venous system is found. When dissection to the flap margins is completed, elevation of the flap is begun along the medial border of the tibia where the deep fascia is inserted. The skin island for the distally based flap is usually located higher than for the standard flap. The island of skin is designed and centered over the distal fourth of the sartorius muscle with the distal extent of the skin island extending just below the knee joint, so that, the pivot point for the arc of rotation is at the level of the knee. The descending genicular vessels as well as the long saphenous vein are ligated and divided to be included in the flap [8,14,18]. However, the saphenous nerve is dissected from the fascial side of the flap and is preserved. During the subfascial dissection, perforators from the posterior tibial artery or the medial gastrocnemius muscle are carefully preserved as possible. Electric coagulation is not used, to avoid damage to the fascial vascular network. The flap is then ready for transposition. Superficial fascia and skin are sutured as separate layers into the edges of the defect. The donor site is closed primarily if less than 6cm. Across and a drain inserted. Variations in vascular anatomy sometimes present, so, it is important to determine whether the cutaneous branches coursing anterior or posterior to the sartorius represent the predominate vascular pedicle. It is essential to select the larger pedicle before designing the skin island [18]. The largest successful flap has measured 5X18cm. Postoperatively, bed rest with elevation

of the extremity was encouraged for 5 days, after which patients were allowed to ambulate. After 10 days, normal activities were resumed (Fig. 2).

Fig. (2) (Case 9) 19 years old female with post-traumatic scar of the popliteal fossa with knee contracture. (A) Post-traumatic scar and contracture of the right medial side of the knee joint. (B) Flap design. (C) Flap elevation with preservation of the saphenous neurovascular bundle by blunt dissection

of sartorius muscle (hanged by the tape) and separating it from vastus medialis muscle. (D) Flap after ligating the saphenous neurovascular bundle and the great saphenous vein at the distal flap margin (the flap includes: Deep fascia, saphenous neurovascular bundle, great saphenous vein, and medial cutaneous nerve). (E) Further dissection of the pedicle to achieve more length. (F) Flap insetted in position with direct closure of the donor site. (G-H) Early post-operative. (I-J) Late post-operative.

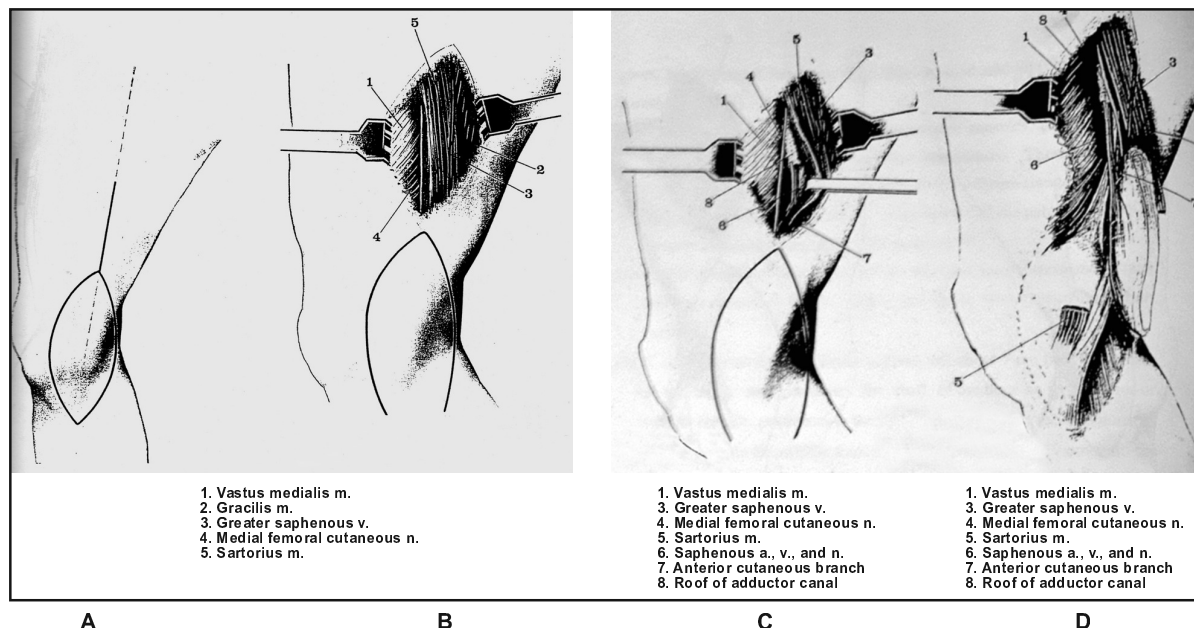


Fig. (1): Anatomy of saphenous flap based on saphenous neurovascular bundle.
(Quoted from Strauch and Yu [16])

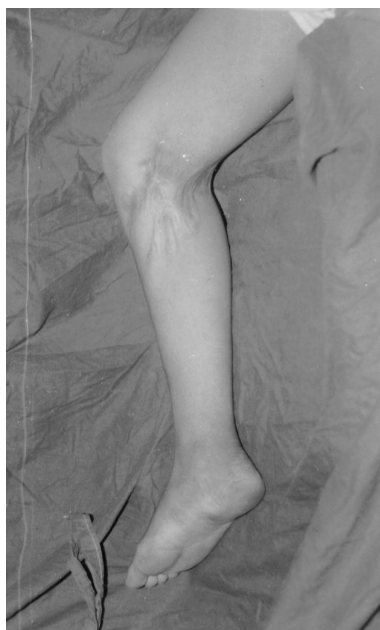

Fig. (2-A)

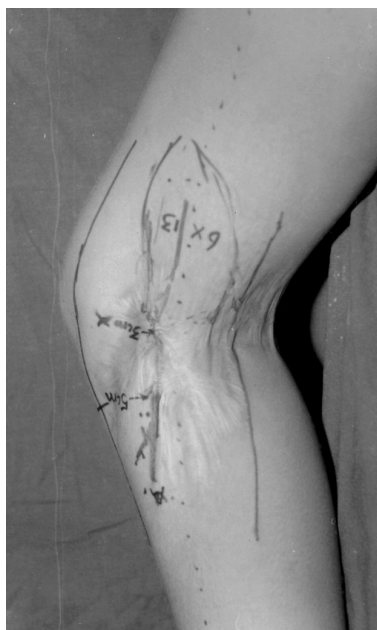

Fig. (2-B)

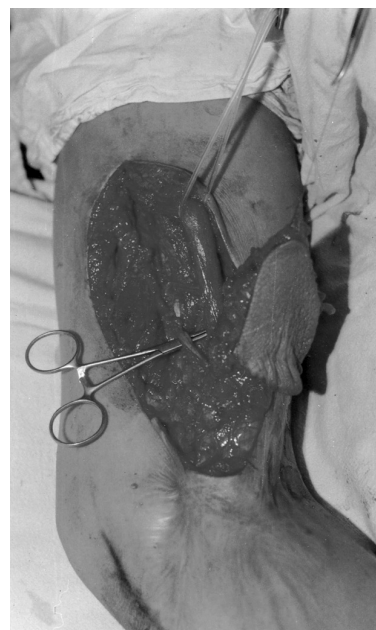

Fig. (2-C)

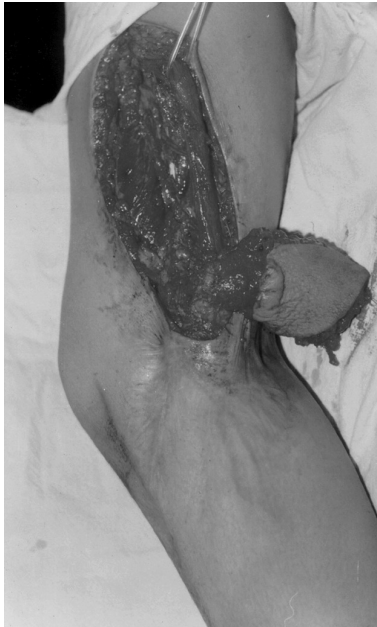

Fig. (2-D)

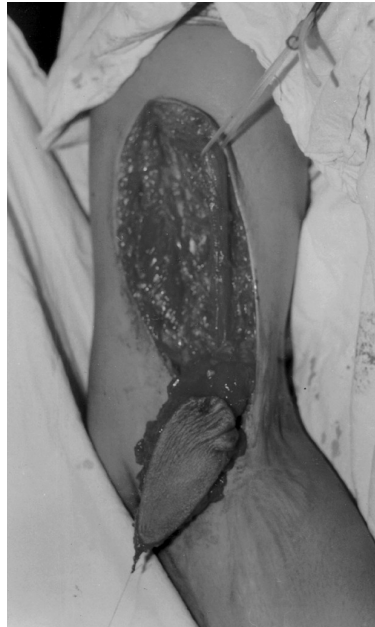

Fig. (2-E)

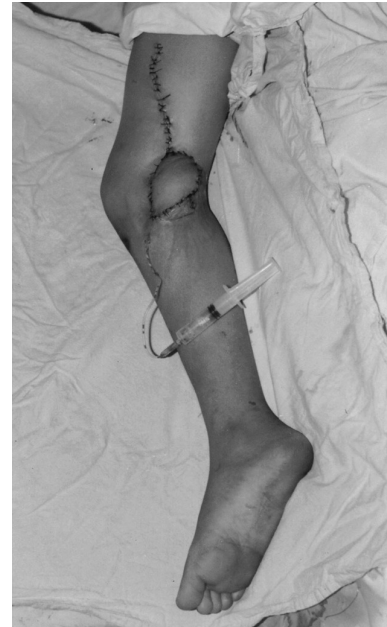

Fig. (2-F)

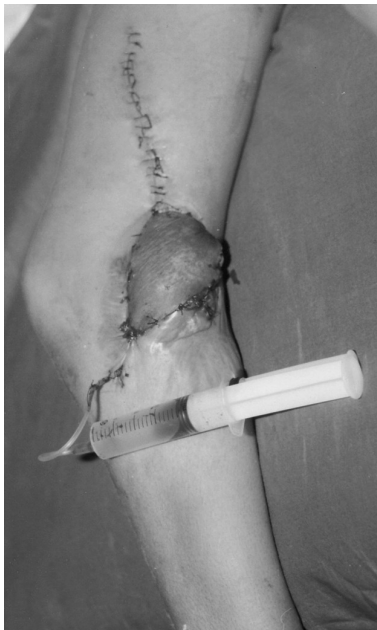

Fig. (2-G)

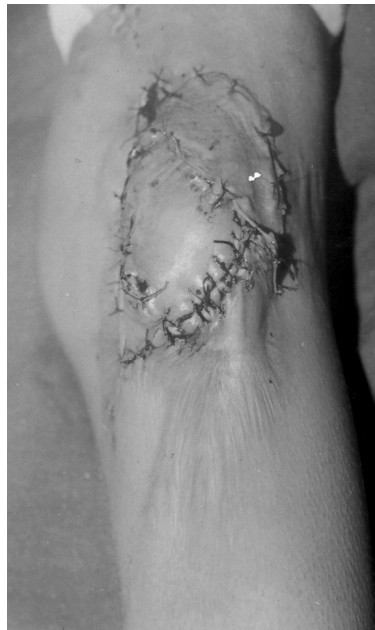

Fig. (2-H)

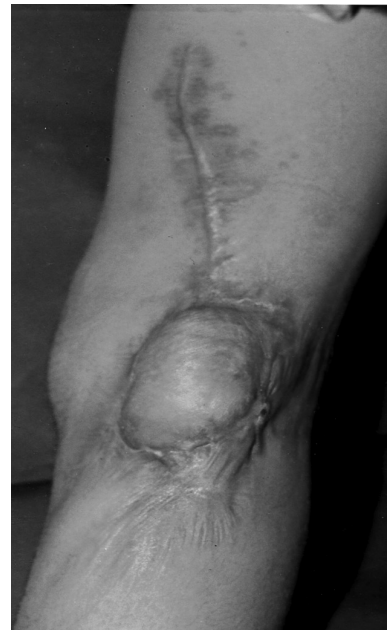

Fig. (2-I)

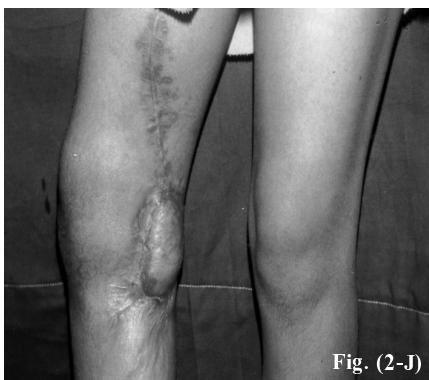

Fig. (2-J)

Fig. (2): (Case 9) 19 years old female with post-traumatic scar of the popliteal fossa with knee contracture. (A) Post-traumatic scar and contracture of the right medial side of the knee joint. (B) Flap design. (C) Flap elevation with preservation of the saphenous neurovascular bundle by blunt dissection of sartorius muscle (hanged by the tape) and separating it from vastus medialis muscle. (D) Flap after ligating the saphenous neurovascular bundle and the great saphenous vein at the distal flap margin (the flap includes: Deep fascia, saphenous neurovascular bundle, great saphenous vein, and medial cutaneous nerve). (E) Further dissection of the pedicle to achieve more length. (F) Flap inset in position with direct closure of the donor site. (G-H) Early post-operative. (I-J) Late post-operative.

RESULTS

From April of 2010 to August of 2012, 12 patients were treated with the distally based saphenous fascio-cutaneous flap with a fascial pedicle (Table 1).

Preoperative data and patient demographics were recorded (Table 2). The average age was 46 years (range, 15 to 64 years). 8 patients were men (66.6%) and 4 (33.3%) were women. Significant comorbidities such as coronary heart disease, hypertension, diabetes mellitus, nicotine smoking, obesity, and chronic venous congestion were encountered in 9 patients (75%). The defects varied in size from 3x4cm to 7x10cm in size with an average of 34.9cm². Distally based Saphenous flap

has been used for soft-tissue reconstruction of defects resulting from acute trauma in five cases (41.6%), tumour resection in two cases (16.6%), and chronic ulcer in three cases (25%). One case (8.3%) was a necrotic wound caused by a corrosive drug and a wound (8.3%) caused by an electricity injury.

Postoperative results were documented (Table 3). The operative time averaged 140 minutes (range, 90 to 170 minutes). The size of the flaps ranged from 5x12cm to 5x18cm with an average of 72.3cm². All flaps had good perfusion and 9 flaps survived completely, partial necrosis of the tip of the flap was encountered in three cases. The donor sites healed uneventfully with minor complications in three patients.

Table (1): Patient details.

No.	Age	Sex	Cause	Defect size	Flap size	Complication
1	38	M	Comminuted tibial plateau fracture	5X6	5X14	Persistent sensory loss
2	52	F	Electrical injury	4X8	5X15	Partial tip necrosis
3	60	M	Ewing sarcoma upper tibia	3X4	5X12	Hematoma
4	35	M	Corrosive chemical injury	6X7	5X15	Flap revision
5	45	F	Avulsion injury with exposed bone	5X9	5X16	Infection caused by plates
6	64	F	Osteosarcoma tibia	3X6	5X13	Persistent sensory loss
7	15	M	Marjulin ulcer upper tibia	7X10	5X18	Flap revision
8	48	M	Unstable scar of chin of tibia	4X5	5X13	Nil
9	19	F	Post-traumatic scar of popliteal fossa & knee contracture	5X7	6X13	Partial tip necrosis
10	64	M	Compound fracture tibia with exposed tendon and bone	3X6	5X12	Nil
11	49	M	Chronic ulcer upper tibia with exposed plate	4X9	5X16	Marginal tip necrosis
12	63	M	Compound fracture upper tibia with osteomyelitis	6X6	5X14	Nil

Table (2): Patient Demographic (Preoperative data).

Item	No.	Percentage
No. of patients	12	
Average age, yr	46	
Male sex	8	66.6
Female sex	4	33.3
Severe comorbidities	9	75
Exposed bone	2	16.6
Traumatic wounds	5	41.6
Tumour resection wounds	2	16.6
Chronic ulcers	3	25
Post-corrosive necrotic wound	1	8.3
Electricity injury	1	8.3
Osteomyelitis	1	8.3
Wound infection	3	25
Average Wound size	34.9cm ²	
Average flap size	72.3cm ²	

Table (3): Postoperative results.

Item	No.	Percentage
Average operative time	140 min.	
Average flap size	72.3 cm ²	
Major complications (requiring surgery)	3	
Partial tip necrosis	2	
Persistent sensory disturbance in the leg	1	
Infection	1	
Hematoma	3	
<i>Donor site complications:</i>		
- Hematoma	1	
- Epidermolysis	1	
- Cellulitis	1	
Successful wound closure	12	
Average follow-up time	21 months	

Two major complications encountered (16.6%) defined as complications requiring operative revision due to wound dehiscence. Partial necrosis of the tip of the flap was encountered in three cases (25%). In 2 cases (16.6%), the saphenous nerve was divided at the upper edge of the flap and was transferred with the flap to the recipient site. Both patients complained of persistent sensory disturbance over the anteromedial aspect of the leg after surgery. The saphenous nerve was preserved in the following ten cases and there was no sensory change postoperatively. In one case (8.3%), infection of the reconstructed site occurred 3 weeks after patient discharge. After the removal of the plates from the tibia and administration of antibiotics, the infection subsided. Hematoma occurred in one case (8.3%).

Complications at the donor site occurred in three patients (25%). These were hematoma in one case (8.3%), epidermolysis in one case (8.3%), and cellulites in one case (8.3%). The average follow-up was 21 months (range, 6 to 30 months).

DISCUSSION

Reconstruction of soft tissue defects around the knee, and superior third of the tibia presents a difficult and challenging problem. The initial enthusiasm for managing these cases with microsurgical free tissue transfer was described by Acland et al. [8] has gradually decreased with the availability of other simple, reliable, and less time consuming surgical procedures designed to treat moderate size noncomplicated wounds. Nevertheless, the role of microsurgical free tissue transfer still remains the method of choice in major soft tissue and bone defects, and Gustillo type IIIb and IIIc injuries [19-22].

A gastrocnemius muscle or musculocutaneous flap is a common local flap for cover of soft tissue defects around the knee and superior third of the tibia [1,10,11]. These flaps have a reliable vascular pedicle and can offer a plentiful supply of tissue for reconstruction. The vastus medialis and lateralis flaps have been especially effective for closure of major soft tissue defects around the knee [12]. Although there is no significant functional loss postoperatively, part of one major muscle of the leg is sacrificed. Soft tissue defects of the lower leg can be associated with injury of the nearby muscles. Utilization of these local muscles for reconstruction may further impair lower extremity function. The dissection of a muscle flap involves a deep surgical plane and there is a possible risk

of injury of a major nerve [22]. Another major drawback of myocutaneous flaps is the obvious deformity of the donor site.

Fasciocutaneous flaps can also be used to cover soft tissue defects of the lower leg. In order to minimise the donor site morbidity, various modifications of the fasciocutaneous flap have been developed [24-26]. Moscona et al. [4] used an island fasciocutaneous flap to cover an injured knee. This flap was elevated from the posterior part of the lower leg.

Gumener et al. [5] described various flaps of fat and fascia of the lower leg, which have less donor site morbidity than fasciocutaneous flaps. They used a flap to cover a defect over the knee.

The anteromedial aspect of the leg is another potential donor site, which is supplied mainly by the saphenous artery. The artery was found to originate from the lateral side of descending genicular artery of the femoral artery at 10-15cm above the knee. Its circumference was ranging from 1.7-2.2mm. The area of skin staining after selective injection of methylene blue of the saphenous artery extends to about 20cm below the knee [8,9]. Saphenous artery is a large artery which can supply a free flap as large as 29x8cm [8]. However, Acland et al., reported that this artery was absent in 4 out of 82 cases [8]. They enumerated the advantages of this flap as: It has a long vascular pedicle, it has a good diameter, easier vascular dissection in tissue planes, thin flap (not exceeding 1cm. in thickness), and excellent dual venous drainage [8]. One interesting feature of the flap is its lymphatic anatomy; two major lymphatic trunks run along the length of the flap immediately next to the long saphenous vein. Thus the flap has the potential to be used as a lymphatic bridge, with direct lymphatic anastomoses proximally and distally [17]. In our patients, we use a distally based saphenous flap and the base of the flap was raised with 5cm width fascial pedicle. This thin, wide pedicle was easy to dissect and to transpose. The flap included the vascular plexus of the medial genicular vessels in addition to the saphenous vessels. However, perforators from the posterior tibial artery or the medial gastrocnemius muscle were incorporated in the pedicle.

In patient 5, infection of the reconstructed site occurred three weeks after she left hospital. After removal of the plates and administration of antibiotics, the infection subsided without loss of soft tissue. The other patients were free of infection. The muscle or musculocutaneous flap has been

recommended as the first choice of flap in the management of chronic osteomyelitis and fibrotic cavities [27,28]. Thatte and Laud [28] used the fascia as a roll-over flap to reconstruct soft tissue defects with exposed tibia. Lin et al. [29] used adipofascial flaps to reconstruct open tibial fractures of Gustilo type IIIB and reported that this flap had an ability to control infection [29,30]. Yaremchuk et al. [31] believed that an adequate obliteration of dead space with conformable tissue was important for the control of wound infection in addition to debridement of devitalised or infected tissue [31]. With no overlying skin, adipofascial flaps of the lower leg are soft and pliable and conform to the recipient site quite nicely to obliterate any dead space. An adipofascial flap can provide stable cover for exposed bone and metal [29,30]. However, if the embedded metal or bone fragment is the source of infection, it should be removed. Adipofascial flap also provided adequate padding for this crucial area with sufficiently stable cover for a second operation.

If the saphenous nerve is divided and included in the fasciocutaneous flap, anaesthesia will occur in the anteromedial aspect of the leg as occurred in case 1 and case 6. In other cases in our series, (except the first and sixth patients) the saphenous nerve was dissected from the flap and was preserved. This dissection did not jeopardize the circulation of the flap. In the other ten cases in which the saphenous nerve was preserved, there was no sensory deficit in the medial aspect of the leg.

Conclusion:

In the present series, the distally based fascial pedicled saphenous flap based on the saphenous artery, great saphenous vein, and saphenous nerve has been shown to be a useful alternative for reconstruction of moderate and large sized soft tissue defects around the knee and superior third of the tibia. It is easy and fast to perform and gave satisfactory results with minimal postoperative morbidity for both donor and recipient sites.

REFERENCES

- 1- Barford B. and Pers M.: Gastrocnemius-plasty for primary closure of compound injuries of the knee. *J. Bone Joint Surg.*, 52: 124-7, 1970.
- 2- Lewis V.L.Jr., Mossie R.D., Stulberg D.S., et al.: The Fascio-cutaneous flap: A conservative approach to the exposed knee joint. *Plast. Reconstr. Surg.*, 85: 252-7, 1990.
- 3- Hallock G.G.: Local knee random Fascio-cutaneous flaps. *Ann. Plast. Surg.*, 23: 289-996, 1989.
- 4- Moscona A.R., Govrin-Yehudain J. and Hirshowitz B.: The island Fascio-cutaneous flap: A new type of flap for defects of the knee. *Br. J. Plast. Surg.*, 38: 512-14, 1985.
- 5- Gumener R., Montandon D., Marty F., et al.: Subcutaneous tissue flap in the limbs: An anatomical and clinical approach. *Ann. Plast. Surg.*, 16: 377-785, 1986.
- 6- Follmar K.E., Baccarani A., Baumeister S.P., Levin L.S., et al.: The distally based sural flap. *Plast. Reconstr. Surg.*, 119: 138e-148e, 2007.
- 7- AlQattan M.M.: The unstable posterior heel scar: Reconstruction using reverse flow sural artery adipofascial flap. *Ann. Plast. Surg.*, 58: 222-223, 2007.
- 8- Acland R.D., Schusterman M., Godina M., et al.: The saphenous neurovascular free flap. *Plast. Reconstr. Surg.*, 67: 763-74, 1981.
- 9- Haertsch P.A.: The blood supply to the skin of the leg: A post-mortem investigation. *Br. J. Plast. Surg.*, 34: 470-7, 1981.
- 10- Feldman J.J., Cohen B.E. and May J.W. (Jr.): The medial gastrocnemius myocutaneous flap. *Plast. Reconstr. Surg.*, 61: 531-9, 1978.
- 11- Arnold P.G. and Mixter R.C.: Making the most of the gastrocnemius muscle. *Plast. Reconstr. Surg.*, 72: 38-48, 1983.
- 12- Auregan J.C., Begue T., Tomeno B., et al.: Distally-based vastus lateralis muscle flap: A salvage alternative to address complex soft tissue defects around the knee. *Orthop. Traumatol. Surg. Res.*, 96: 180-184, 2010.
- 13- Lin S.D., Lai C.S., Chou C.K., et al.: Reconstruction of soft tissue defects of the lower leg with the distally based medial adipofascial flap. *Br. J. Plast. Surg.*, 47: 132-27, 1994.
- 14- Cormack G.C. and Lamberty B.G.H.: The arterial anatomy of skin flaps. Edinburgh: Churchill Livingstone, 368-870, 1986.
- 15- Carrihuiry C., Costa M.A. and Vasconez L.O.: An anatomic study of the septocutaneous vessels of the leg. *Plast. Reconstr. Surg.*, 16: 354-463, 1985.
- 16- Strrauch B. and Yu H.L.: Lower leg and knee, saphenous flap. (1st Ed.): In *Atlas of microvascular surgery: Anatomy and operative approaches*. Published by Thieme medical publisher Inc., New York, pp. 252-256, 1993.
- 17- Serafin D.: Fascial-Fasciocutaneous flaps, the saphenous flap. In *Atlas of microvascular composite tissue transplantation*. Philadelphia, Pennsylvania. W.B. Saunders Co. pp. 453-458, 1996.
- 18- Mathes S.J. and Nahai F.: Thigh, Saphenous flap. In *Reconstructive surgery, principles, anatomy, and technique*. Churchill Livingstone Inc. pp. 1247-1259, 1997.
- 19- Byrd H.S., Spicer R.E. and Clerry G.: Management of open tibial fractures. *Plast. Reconstr. Surg.*, 76: 719-728, 1985.
- 20- Godina M.: Early microsurgical reconstruction of complex trauma of the extremities. *Clin. Plast Surg.*, 13: 619-620, 1986.
- 21- Hollenbeck S.T., Woo S., Komatsu I., et al.: Longitudinal outcomes and application of the subunit principle to 165

- lower limb free tissue transfers. *Plast. Reconstr. Surg.*, 125: 942-943, 2010.
- 22- Egozi D., Fodor L. and Ulmann S.: Salvage of compromised free flaps in trauma cases with combined modalities Microsurgery, 31: 109-115, 2011.
- 23- Hallock G.G.: Relative donor site morbidity of muscle and fascial flaps. *Plast. Reconstr. Surg.*, 92: 70-6, 1993.
- 24- Rois-Luna A., Villanueva-Martinez M., Fahandezh-Saddi H., et al.: Versatility of the sural fasciocutaneous flap in coverage defects of the lower limb. *Injury*, 38: 824-831, 2007.
- 25- Teo T.C.: The propeller flap concept. *Clin. Plast. Surg.*, 37: 615-626, 2010.
- 26- Petry J.J. and Walton R.L.: Follow-up on the posterior calf fasciocutaneous free flap. *Plast. Reconstr. Surg.*, 76: 149-51, 1985.
- 27- Mathes S.J., Alpert B.S. and Chang N.: Use of the muscle flap in chronic osteomyelitis: Experimental and clinical correlation. *Plast. Reconstr. Surg.*, 69: 815-29, 1982.
- 28- Rusell R.C., Graham D.R., Feller A.M., et al.: Experimental evaluation of the antibiotic carrying capacity of a muscle flap into a fibrotic cavity. *Plast. Reconstr. Surg.*, 81: 162-270, 1988.
- 29- Thatte R.L. and Laud N.: The use of the fascia of the lower leg as a roll-over flap: It's possible clinical applications in reconstructive surgery. *Br. J. Plast. Surg.*, 37: 888-94, 1984.
- 30- Lin S.D., Lai C.S., Tsai C.C., et al.: Clinical application of the distally based medial adipofascial flap for soft tissue defects on the lower half of the leg. *J. Trauma*, 38: 623-9, 1995.
- 31- Yaremchuk M.J., Brumback R.J., Manson P.N., et al.: Acute and definite management of traumatic osteocutaneous effects of the lower extremity. *Plast. Reconstr. Surg.*, 80: 1-14, 1987.